



# Effects of Spinal Decompressor (DRX9000) for Lumbar Disc Herniation

As published in:  
The Journal of Saitama Kenou Rehabilitation  
Vol. 6 November 1, 2006 | Kawagoe, Japan



9423 Corporate Lake Drive  
Tampa, Florida 33634  
Tel: 813-249-6444 Fax: 813-249-6445  
[www.AxiomWorldwide.com](http://www.AxiomWorldwide.com)



Asakusa Kannon Temple  
The oldest temple in Tokyo, Japan.

**Naoyuki Oi**, Department of rehabilitation medicine, Saitama medical university, Saitama medical center; **Akira Itabashi**, Saitama center for bone disease; **Shusuke Kusano**, Department of rehabilitation medicine, International university of health and welfare, Mita hospital; **Mitsuru Yamamoto**, Department of rehabilitation medicine, Saitama medical university, Saitama medical center; **Mutsuo Yamada**, Department of rehabilitation medicine, Saitama medical university, Saitama medical center; **Yasuyuki Takakura**, Department of rehabilitation medicine, Saitama medical university, Saitama medical center; **Keigo Kumamoto**, Department of rehabilitation medicine, Saitama medical university, Saitama medical center; Tetsuo Suyama, Department of rehabilitation medicine, Saitama medical university, Saitama medical center

1) Naoyuki Oi, 2) Akira Itabashi, 3) Shusuke Kasano, 1) Mitsuru Yamamoto,  
1) Mutsuo Yamada, 1) Yasuyuki Takakura, 1) Keigo Kumamoto 1) Tetsuo Suyama

- 1) Department of rehabilitation medicine, Saitama medical university, Saitama medical center.
- 2) Saitama center for bone disease.
- 3) Department of rehabilitation medicine, International university of health and welfare, Mita hospital.

### Abstract

We reported a clinical result of a treatment of lumbar disc Herniation (LDH) patients by using a traction device (DRX9000), which decompresses intervertebral disc with logarithmic-curve traction. Changes of intervertebral disc on radiogram in healthy persons without hernia at the traction by DRX9000 were reported as well. Subjects were seven LDH patients (5 women, 2 men). The mean age was 47 years old (32-72). The traction treatment was continued for four to six months. The treatment was finished in four patients of seven. In these four cases, obvious improvements of symptoms were recognized in VAS values and Japan Orthopedic Association score. The LDH shrinkage was recognized in three patients of four on the MRI image at the time of completion of the treatment. In this study, the intervertebral disc spaces of healthy persons without hernia were recognized to expand by 7-12% during the traction with DRX9000 compared to that before the traction. It appeared that DRX9000 was effective for lumbar disc Herniation.

**Key Words:** Pelvic traction, Herniated nucleus pulposus, Lumbar spine.

### [Objective]

As a treatment of lumbar disc Herniation (LDH), pelvic traction has been performed since a fairly old time. The effect of pelvic traction had been thought not to decompress nerve roots by the direct traction on intervertebral disc and reposition of hernia there but only to withdraw inflammation of sciatic nerve by reducing lumbar lordosis and keeping rest. 3-5), 7), 8) This time we reported a clinical result of a treatment of LDH patients by using a traction device (DRX9000), which decompresses intervertebral disc with logarithmic-curve traction. 6) Changes of intervertebral disc on radiogram in healthy persons without hernia at the traction by DRX9000 were reported as well.

### [Materials & Methods]

Subjects were LDH patients, which consisted of five women and two men with the mean age of 47 years old (32-72). LDH type on MRI before the treatment was classified into extrusion type six, and sequestration type one. After the lapse of three weeks or more from the acute stage and a slight improvement of symptoms, the traction treatment by DRX9000 was performed twice a week. The final strength of traction was settled as a half of patient's weight and the starting strength was 70-80% of the final. After that the strength was increased gradually and adjusted according to changes of each symptom. The traction treatment was continued for four to six months

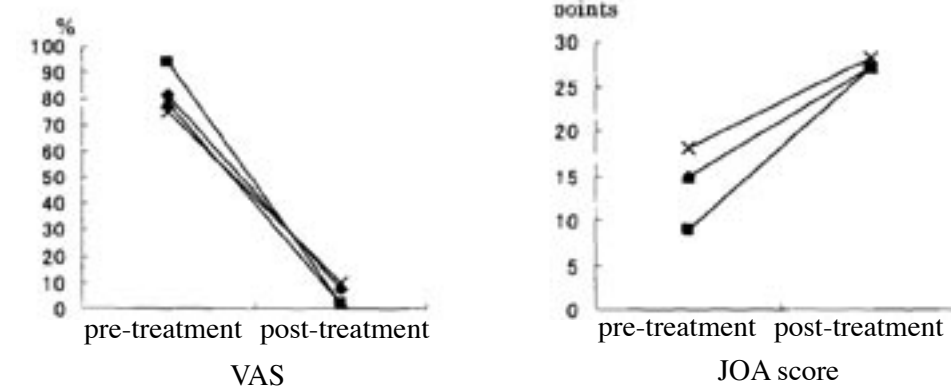


Fig. 1: Changes VAS score and Japan Orthopedic Association score between before and after treatment.

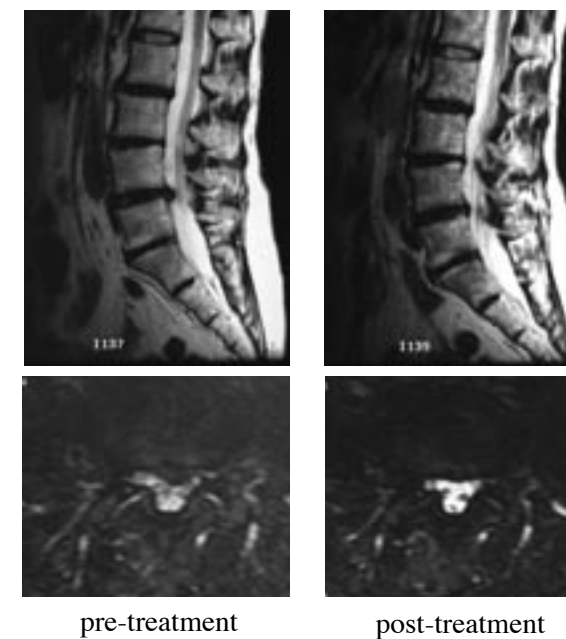


Fig. 2: Case 1; 63-year-old female. L4-L5 lumbar disc herniation (LDH).

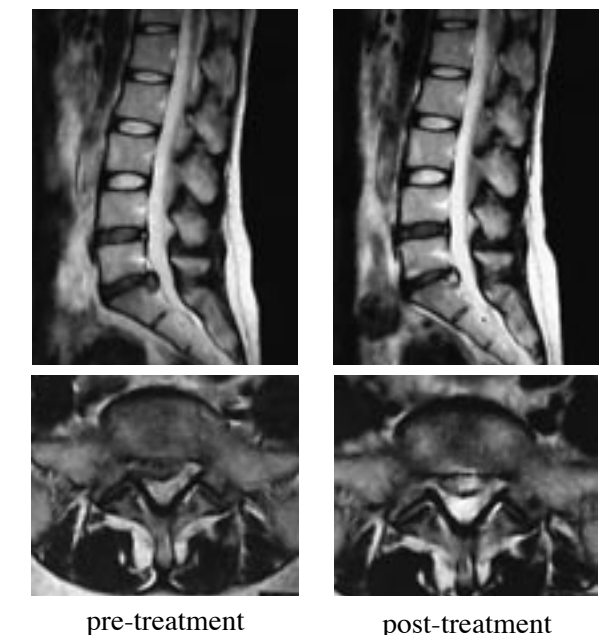


Fig. 3: Case 2; 41-year-old female. L5-S1 LDH.

and during these months, physical therapy such as muscle training of the trunk and lower limbs as well as stretching exercise of lower-limb muscles was held once a week. Epidural blocks or NSAIDs was performed along with the said training in some cases. After the completion of the treatment, MRI was held again and morphological

changes of LDH were compared with those of MRI before the treatment. In addition, symptom changes between the start of the treatment and the completion of the treatment were evaluated according to VAS values of pains and Japan Orthopedic Association score (JOA score).

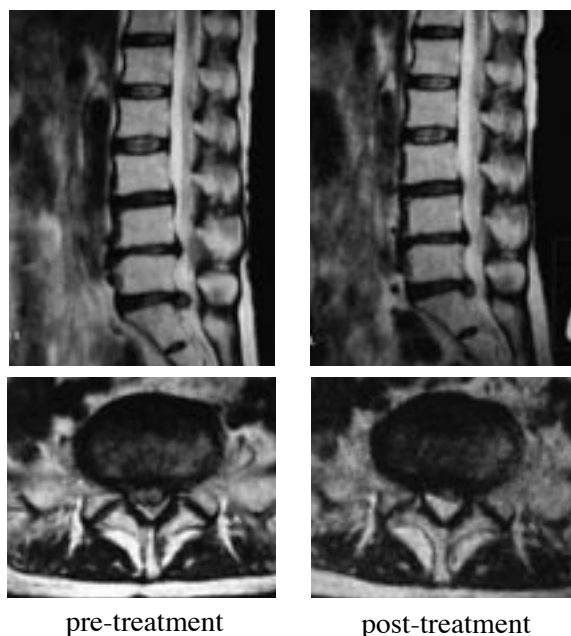


Fig. 4: Case 3; 71-year-old female. L5-S1 LDH.

Next, lateral radiograms of lumbar spine of two healthy men without hernia before and during the traction were pictured to grasp morphological changes of intervertebral disc during the traction by DRX9000. Radiograms were digitalized by a scanner and the area of intervertebral disc space on the image was measured with Scion image (Release alpha 4.0.3.2), an imaging software on a personal computer. Two evaluators of a doctor and a radiologic technician measured the area five times each to calculate the mean as the final area.

## [Results]

The traction treatment was stopped in three patients of seven at two weeks (one) and four weeks (two) after the start of the treatment. Sciatic pain was slightly remained in two patients of three at the start of the treatment. The treatment for

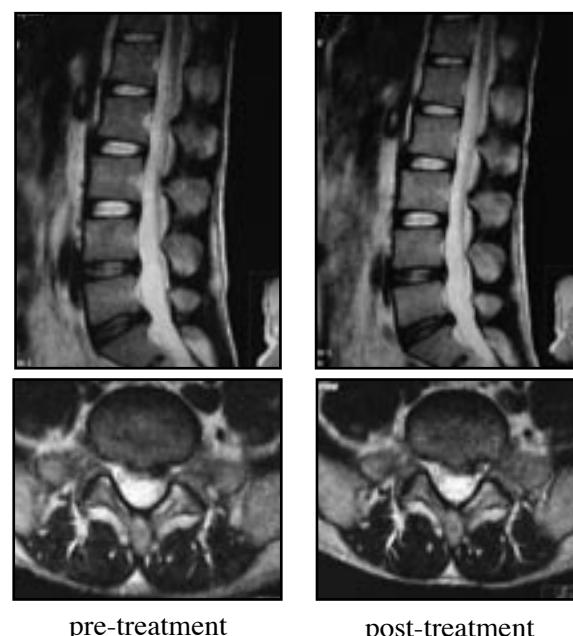


Fig. 5: Case 4. 36-year-old male. L5-S1 LDH.

four to six months was finished in four patients of seven. SLR test was negative in all the cases in the completion of the treatment. VAS values of pains in lumbar and lower limbs decreased from  $82.0 \pm 8.4$  before the treatment to  $5.5 \pm 4.1$  at the completion of the treatment. JOA score increased from  $14.3 \pm 3.8$  before the treatment to  $27.3 \pm 0.5$  at the completion of the treatment (Fig.1).

LDH obviously shrunk compared to that before the treatment in the three patients of four in the MRI finding in the completion of the treatment. Case 1 was a woman aged 63 and LDH of extrusion type was recognized between the fourth and fifth lumbar vertebrae. The traction treatment with DRX9000 was performed 25 times in total for about four months. Compared to that before the treatment, LDH obviously shrunk in the completion of the treatment (Fig. 2). Case 2

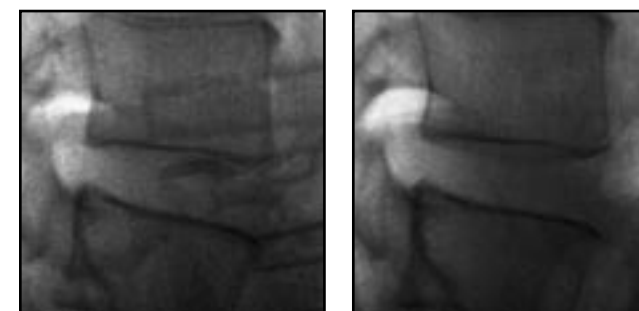


Fig. 6: A healthy person. 1. 35-year-old male.

was a woman aged 41 with sciatic pain in the right lower limb and LDH of extrusion type was recognized between the fifth lumbar vertebra and the first sacral vertebra. The treatment was held 27 times in total for about 4.5 months. Compared to that before the treatment, the intensity of LDH changed on MRI image (T2 weighted image) and the degree of protrusion to the spinal canal, especially to the right root tunnel, decreased (Fig. 3). Case 3 was a woman aged 71 with sciatic pain in the right lower limb and LDH of extrusion type was recognized between the fifth lumbar vertebra and the first sacral vertebra. The treatment was held 42 times in total times for about six months. Compared to that before the treatment, LDH obviously shrunk in the completion of the treatment (Fig. 4). Case 4 was a man aged 36 with sciatic pain in the left lower limb and LDH of extrusion type was recognized between the fifth lumbar vertebra and the first sacral vertebra. The treatment was held 18 times in total for about four months. Though the symptoms seemed to be removed, the MRI finding showed no change in the completion of the treatment compared to that before the treatment (Fig. 5).

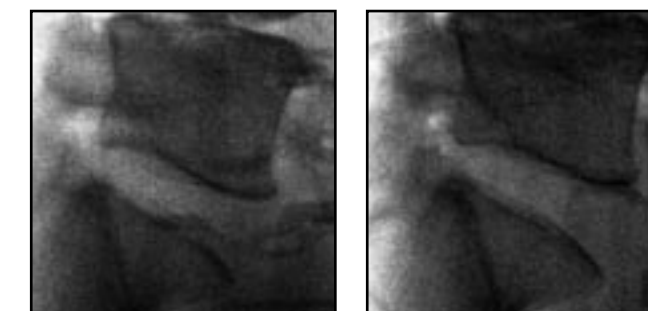


Fig. 7: A healthy person. 2. 48-year-old male.

The area of an intervertebral disc space between the fourth and fifth lumbar vertebra of a healthy person 1 without hernia increased by 12% than that before traction (Fig. 6); the area between the fifth lumbar vertebra and the first sacral vertebra of a healthy person 2 increased by 7% than that before traction (Fig. 7). The said areas were measured on the lateral radiogram during traction.

## [Discussion]

A clinical outcome study of the effect of spinal Decompressor (DRX9000) showed that 86% of 219 patients with herniated and degenerative disc disease reported immediate resolution of symptoms, while 84% remained pain-free 90 days post-treatment. 6) DRX9000 is the device for pelvic traction with logarithmic-curve traction. Compared to conventional pelvic-traction device with rectilinear traction, the decompressive effect in the intervertebral disc space is said to be greater in the DRX9000. According to the explanation of developers of DRX9000, because reactive contraction of the trunk muscle hardly occurs in the traction, the intervertebral disc space expands. It is said that the resulted decompressive effect probably repositions LDH within the intervertebral

disc. In this study, the intervertebral disc spaces of healthy persons without hernia were recognized to expand by 7-12% during the traction with DRX9000 compared to that before traction. This suggested the possibility of decompression in the intervertebral disc space.

As for clinical results of LDH patients this time, obvious improvements of symptoms were recognized in VAS values and JOA score in pains of lumbar and lower limbs of patients with the completion of treatment by using DRX9000 for four to six months. In addition, LDH shrinkage was recognized in three patients of four on the MRI image. However, the possibility of LDH reposition within the intervertebral disc to cause the shrinkage were extrusion type. 1), 2) LDH shrinkage shall be caused by the addition of mechanical stress around LDH to result in the change of epidural blood stream to promote phagocytosis by inflammatory cells. Moreover, because LDH withdrawal was recognized as a natural course in sequestration type, the treatment result this time shall be probably be considered only the natural course. However, LDH withdrawal as a natural course for a short period of four months shall hardly be possible. Morphological changes of LDH shown this time were regarded as a treatment result by DRX9000 in spite of the unclarified mechanism of action. It appeared that DRX9000 was effective for lumbar disc herniation.

In addition, no change was recognized in the size of LDH in one patient of four with the completion of the treatment despite the improvement of symptoms. In this case, the

number of traction was only 18, which was less than the other cases with LDH shrinkage. Less number of traction was considered the reason for no shrinkage of LDH on the MRI image.

Among seven patients with DRX9000 treatment this time, two had an advancement of irritative symptoms of sciatic nerve to lead the discontinuance of the treatment. The recognized effect of expansion of intervertebral disc space shall bring the patients the recurrence of sciatic pain. The starting time of the traction treatment and the modification of traction strength shall fully be considered.

As future subjects in the study, the comparison between the treatment results of LDH by DRX9000 and those by conventional pelvic traction device, and the relationship between the time of treatment and the LDH shrinkage shall be cited.

### **[Conclusion]**

The spinal decompressor (DRX9000) showed a slight expansion of lumbar intervertebral disc and the improvement of clinical symptoms of lumbar disc Herniation (LDH). At the time of the completion of the treatment by DRX9000, LDH on the MRI image were discovered to shrink compared to that before the treatment in some cases. In cases with the remaining symptoms at the acute stage, symptoms advanced with the traction treatment to lead the discontinuance of the treatment.

### **[References]**

- 1) Bogduk N. and Twomey L.T., Clinical anatomy of lumbar spine. Longman, UK 1987.
- 2) Burton C.V., Gravity Lumbar Reduction, Managing low back pain. Edited by Krikaldy-Willis W.H., Churchill Livingstone, New York, 1983.
- 3) Cailliet R., Understand your Backache. F.A. Davis Co., Philadelphia 1985.
- 4) Cailliet R., Low back pain syndrome. 3rd ed. F.A. Davis Co., Philadelphia 1981.
- 5) Finneson B.E., Low back pain. 2nd ed. Lippincott Co., Philadelphia 1980.
- 6) Gionis T.A. and Groteke E., Spinal decompression. Orthopedic technology review, 5:36-39, 2003.
- 7) Macnab I., Backache. Williams & Wilkins Co., Baltimore 1977.
- 8) Ooi Y., Conservative treatments for lumbar disc diseases. Orthopedic Mook 11:31-43, Kanehara Shuppan, Tokyo 1979.